
A Comparative Analysis of Sonographic Interpretation of Peripheral Nerves in the Anterior Compartment of the Forearm Between an Experienced and Novice Interpreter

Laurie Y. Hung, DC, Octavian C. Lucaciu, MD, PhD, and David M. Soave, MSc,
Canadian Memorial Chiropractic College

Purpose: This article describes a pilot study that compares the ability of a novice interpreter and an experienced interpreter to interpret ultrasound images of peripheral nerves in the anterior compartment of the forearm. **Methods:** Twenty subjects between 18 and 50 years of age were included. A student was taken through tutorials in which she was guided through identification of the peripheral nerves of the anterior forearm. After the tutorials, the experienced interpreter traced the subjects' ulnar nerve and artery neurovascular bundle proximally in the anterior compartment of the forearm until just before it separated into the artery and nerve. Here the distance between the median and ulnar nerve was measured by the investigators. The Bland and Altman design and paired *t* tests were used to compare the agreement between the results of the two investigators. **Results:** The Bland and Altman analysis reveals that the difference between two sets of measurements (experienced investigator vs. student) is calculated to be 0.08 mm \pm 0.22 mm for the left arm and 0.16 mm \pm 0.43 mm for the right arm. A paired *t* test revealed that there is no significant difference in the measurements obtained by the two investigators (left arm: *p* = .12; right arm: *p* = .10). These results suggest that the measurements of the two investigators may be interchangeable. **Conclusions:** This pilot study shows that after tutorials combining dissection and sonographic interpretation, the ability of a novice interpreter to identify ultrasonographic images of peripheral nerves in the anterior compartment of the forearm is comparable to that of an experienced interpreter. (J Chiropr Educ 2012;26(1):47-50)

Key Indexing Terms: Diagnostic Imaging; Median Nerve; Peripheral Nerves; Teaching; Ulnar Nerve; Ultrasonography

INTRODUCTION

The use of ultrasonography to visualize peripheral nerves began with the introduction of high-frequency linear array transducers in the 1980s.¹ Many studies have confirmed that deep peripheral nerves (eg, radial, ulnar, median, sciatic) can be regularly visualized with ultrasound imaging.¹⁻³ Clinically, this method of imaging has gained application as a diagnostic tool.⁴ Ultrasonography has been found to be useful in a broad array of nerve pathologies, such as nerve compression, nerve lesions, perineural fibrosis and nerve tumors, and hereditary neuropathies.⁵⁻⁷

Because peripheral nerve pathology is a significant component in the chiropractic scope of practice, diagnostic ultrasound would be a valuable noninvasive, low-cost instrument. The integration of diagnostic ultrasound interpretation of peripheral nerves to the practice of chiropractors and other health care providers may broaden their clinical skills; ultrasound imaging may allow for confirmation of nerve pathology as opposed to clinical suspicion. Currently, there is a paucity of studies examining the feasibility of teaching chiropractic students ultrasound interpretation. This article illustrates an observational pilot study that compares the ability of a novice interpreter (senior chiropractic student) and an experienced interpreter to interpret ultrasound images of peripheral nerves in the anterior compartment of the forearm.

METHODS

Subjects

Twenty subjects (10 female, 10 male) between 18 and 50 years of age, with no upper limb nerve or upper extremity pathologies, were included in this study. This study was approved by the Canadian Memorial Chiropractic College Research Ethics Board. Subjects were recruited through school e-mails and advertisements, and informed written consent was obtained from each subject before the investigation. The experienced interpreter, who also served as the primary investigator of this study, is a medical doctor experienced in diagnostic ultrasound. A novice interpreter, a senior chiropractic student, was taken through two 1-hour tutorials of hands-on ultrasound interpretation with the primary investigator, where the student was guided through identification of peripheral nerves of the anterior forearm in live and recorded ultrasound images. As well, the student was guided through a 1-hour dissection review of the anterior compartment of the forearm with emphasis on the course of the median and ulnar nerves, radial and ulnar arteries, and the spatial relationships between them and the flexor group of muscles in the compartment. In addition to the above, the student also completed reading assignments such as referenced journal articles and textbook chapters on the ultrasonography of peripheral nerves.

Ultrasonography Imaging and Analysis

This study used ultrasonography to investigate the distance between the median and ulnar nerve as they course through the forearm, specifically in the transverse plane at the level at which the ulnar nerve and artery join to form a neurovascular bundle.^{8,9} The particular site for this ultrasound investigation was chosen for the following reasons: (1) it allows for the identification of deep peripheral nerves, namely the median and ulnar nerves; (2) it allows for the identification of the ulnar artery and its spatial relationship to the nerves as it courses through the forearm; and (3) it allows for the identification of the spatial relationship of the median and ulnar nerves to the flexor digitorum superficialis, flexor carpi ulnaris, and flexor digitorum profundus. Ultrasound images were captured using a 35-mm, 6- to 15-MHz linear ultrasound probe (Ultrasonix, British Columbia, Canada).

Each subject was placed in a supine position, with the shoulder at 40° of abduction and the elbow and wrist in a neutral position. The patient's position used for this investigation was chosen based on previous studies. According to Dilly et al, shoulder abduction does not cause ulnar nerve movement in the forearm or arm.¹⁰ Therefore, 40° of abduction was used because this positioning puts little tension on the ulnar nerve and causes minimal movement distally.¹⁰ The primary investigator recorded the ultrasound images.

The first part of the investigation involved placing the transducer transversally in the middle part of the anterior compartment of the forearm and the identification of the ulnar nerve and artery as they course through the anterior compartment of the forearm. This neurovascular bundle was then traced proximally until just before it separated into the artery and nerve.

At this level, both the ulnar and median nerves were identified and 1-second-long sequences of 10 frames were recorded using a frequency of 10.0 MHz at a depth of 3.0 cm. No live measurements were performed during the ultrasonographic investigation. The distance between the median and ulnar nerves at the site of investigation was measured during the second part of the investigation, with the investigators blinded to each other. For this purpose, the ultrasound images were converted into digital format still images and analyzed independently offline using Image Tool 3 (IT3) software. Resolution of the images was 96 dots per inch (dpi) horizontally and 96 dpi vertically, and the image size was 856 × 643 pixels. The IT3 software was then used to calibrate the images according to the depth used during image capture. The distances between the ulnar and median nerves were measured in all participants bilaterally.

Statistics

The Bland and Altman design was used to compare the agreement between the results provided by the two investigators.¹¹ It involves plotting the differences in measurements against their means along with the limits of agreement set as the mean difference \pm 2 SD, thus providing the investigator with a reliable estimation of the size of discrepancy to expect. In addition it provides a visual understanding as to whether the discrepancy is consistent or if it changes over the spectrum of possible varied anatomy between the two nerves. Paired *t* tests were also used in support of this graphical analysis.

RESULTS

The results of the Bland–Altman analysis can be seen in Figures 1 and 2. The average difference between two sets of measurements (experienced investigator vs. student) is calculated to be $0.08 \text{ mm} \pm 0.22 \text{ mm}$ for the left arm and $0.16 \text{ mm} \pm 0.43 \text{ mm}$ for the right arm. There is no relationship between the difference of the two measurements and their means for either the left or right forearm. Because of this, we can summarize the lack of agreement with the limits of agreement, which are calculated as the mean difference plus or minus two standard deviations. From these limits, we determine a maximum discrepancy of 1.02 mm between the two raters. Therefore, we can assume that approximately 95% (limits of agreement = mean \pm 2 SD) of the differences in nerve measurements made by two similar investigators on a similar sample will be less than 1 mm. A paired t test comparing the data from the two investigators showed that there is no significant difference in the measurements obtained by the two investigators (left arm: $p = .12$; right arm: $p = .10$). The mean distances measured between the median and ulnar nerves at the site where the ulnar neurovascular bundle is formed, for the primary and secondary investigators, were $2.23 \pm 0.61 \text{ cm}$ and $2.15 \pm 0.59 \text{ cm}$, respectively.

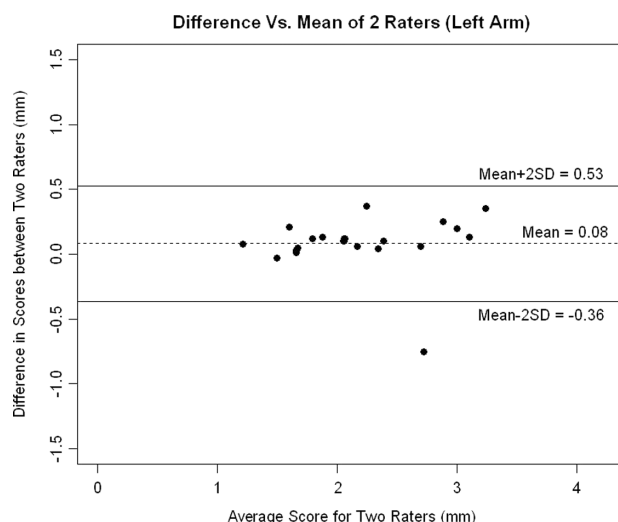


Figure 1. The differences between measurements by two raters against their mean using ultrasonographic imaging (left arm). Limits of agreement (solid line).

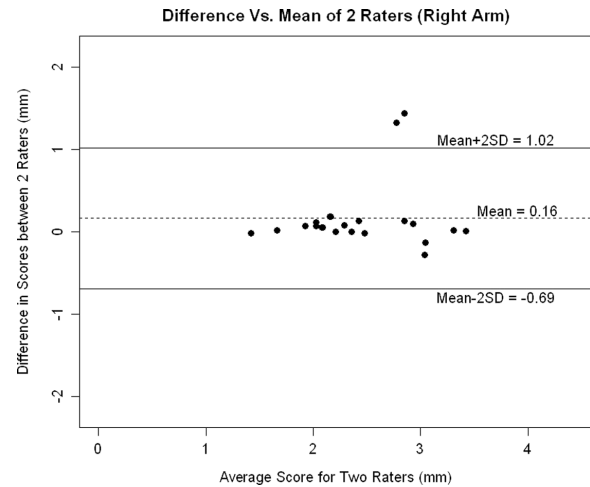


Figure 2. The differences between measurements by two raters against their mean using ultrasonographic imaging (right arm). Limits of agreement (solid line).

DISCUSSION

Overall, from the calculated limits of agreement and the paired t test for each of the analyses (distance between the median nerve and the ulnar neurovascular bundle in the left and right forearms), it appears that the discrepancies between the two investigators are not statistically significant (maximum discrepancy of 1.02 mm). Based on statistical analysis of the data, we can conclude that the results of the two investigators in this study may be interchangeable. These results suggest that it may be feasible to teach ultrasound imaging of peripheral nerves to chiropractic students using anatomical dissection and live and recorded ultrasound imaging.

This pilot study shows that the translation of anatomical content from the chiropractic curriculum into an ultrasonographic setting can be smoothly performed and may suggest room for curriculum enhancement. Clinically, our results suggest that chiropractors and other health care providers not experienced in ultrasound image interpretation may still use ultrasound imaging effectively, based on anatomical knowledge, to examine nerves of the peripheral nervous system in the upper limb. This added diagnostic tool, in addition to history taking and physical examination, may potentially allow for more accurate diagnosis of nerve pathology. The use of ultrasound imaging may also allow for clearer communication between chiropractors and other health care providers when jointly managing patients with nerve pathologies.

The major limitation to this pilot study was the small sample size of $n = 1$. The present study focused on normal anatomy because normal anatomy is traditionally taught before pathology. This study did not examine the ability of a novice interpreter to obtain or read live images in order to blind investigators to each other while comparing interpretation of identical images. Based on these results, the authors feel that a follow-up study with a larger sample size ($n = 10$ or higher) is warranted. Future studies may want to explore ultrasound interpretation of nerve pathology in addition to normal anatomy, as well as the ability of chiropractic students to obtain or read live recordings.

CONCLUSION

This pilot study suggests that after hands-on tutorials that combined instruction in dissection and sonographic interpretation, the ability of a novice interpreter to identify ultrasonographic images of peripheral nerves in the anterior compartment of the forearm is comparable to that of an experienced interpreter. The interpretation of diagnostic ultrasound of peripheral nerves may broaden the clinical skills of chiropractors and other health care providers.

CONFLICTS OF INTEREST

The authors have no conflicts of interest to declare.

About the Authors

Laurie Y. Hung is in private chiropractic practice in Richmond Hill, Ontario, Canada, and a recent graduate of the Canadian Memorial Chiropractic College. Octavian

C. Lucaciu is an Associate Professor of Anatomy at Canadian Memorial Chiropractic College. David M. Soave is a Research Methodologist in the Division of Graduate Education and Research at Canadian Memorial Chiropractic College. Address correspondence to Laurie Y. Hung, 20 Gardiner Crescent, Richmond Hill, Ontario, Canada, L4B 2G5 (e-mail: laurieykhung@gmail.com). This article was received January 6, 2011, revised May 7, 2011, and accepted May 8, 2011.

REFERENCES

1. Fornage BD. Peripheral nerves of the extremities: imaging with US. *Radiology* 1988;167:179–82.
2. Heinemeyer O, Reimers CD. Ultrasound of radial, ulnar, median, and sciatic nerves in healthy subjects and patients with hereditary motor and sensory neuropathies. *Ultrasound Med Biol* 1999;25(3):481–5.
3. McCartney CJL, Xu D, Constantinescu C, Abbas S, et al. Ultrasound examination of peripheral nerves in the forearm. *Reg Anesth Pain Med* 2007;32:434–9.
4. Bianchi S. Ultrasound of the peripheral nerves. *Joint Bone Spine* 2008;75:643–9.
5. Beekman R, Visser LH. High-resolution sonography of the peripheral nervous system—a review of the literature. *Eur J Neurol* 2004;11:305–14.
6. Peer S, Harpf C, Willeit J, et al. Sonographic evaluation of primary peripheral nerve repair. *J Ultrasound Med* 2003;22:1317–22.
7. Quinn TJ, Jacobson JA, Craig JG, van Holsbeeck MT. Sonography of Morton's neuromas. *Am J Radiol* 1999;174:1723–8.
8. Peer S, Bodner G. High-resolution sonography of the peripheral nervous system. 2nd revised ed. Berlin and Heidelberg: Springer-Verlag; 2008.
9. Kathirgamanathan A, French J, Foxall GL, et al. Delineation of distal ulnar nerve anatomy using ultrasound in volunteers to identify an optimum approach for neural blockade. *Eur J Anaesthesiol* 2009;26(1):43–46.
10. Dilley A, Summerhayes C, Lynn B. An in vivo investigation of ulnar nerve sliding during upper limb movements. *Clin Biomech* 2007;22:774–9.
11. Bland JM, Altman DG. Statistical methods of assessing agreement between two methods of clinical measurement. *Lancet* 1986;i:307–10.